

# A Study Ex Vivo of the Effect of Epicardial Fat on the HeartLander Robotic Crawler

N. A. Patronik<sup>1</sup>, M. A. Zenati<sup>2</sup> and C. N. Riviere<sup>3</sup>

<sup>1</sup> Atrial Fibrillation Division, St. Jude Medical, New Brighton, MN, USA

<sup>1</sup> Harvard Medical School, BHS Dept. of Cardiothoracic Surgery, West Roxbury, MA, USA

<sup>2</sup> The Robotics Institute, Carnegie Mellon University, Pittsburgh, PA, USA

*Abstract*— A tethered epicardial crawling robot known as HeartLander has been developed for minimally-invasive surgery on the beating heart. The crawler has been tested in vivo many times in a porcine model, a model which provides generally authentic conditions in many ways; however, the pigs tested generally have little epicardial fat, whereas the epicardial fat in human patients will be considerable. As a result, it is necessary to determine the effect of such fat on the performance of the crawler. In one experiment, using fresh ovine hearts ex vivo, clogging of the suction chambers of the crawler during sliding over tissue with active suction was investigated for a variety of thicknesses of epicardial fat. In a second experiment, the maximum traction force during each step was measured when sliding with active suction repeatedly over the same location for a variety of fat thicknesses. The clogging experiment showed accumulation of fat in the suction chamber, with the amount dependent on the state of the epicardial membrane, but the suction line did not clog. The traction experiment showed that traction was maintained in all cases except when the epicardial membrane was excised completely.

*Keywords*— Medical robotics, minimally invasive surgery, cardiac surgery, instrumentation.

## I. INTRODUCTION

A minimally-invasive approach to cardiac surgery has long been recognized as desirable in order to avoid the morbidity associated with large incisions [1]. In order to avoid also the morbidity associated with cardiopulmonary bypass, there have been increasing efforts in recent years toward the goal of minimally-invasive surgery on the beating heart, i.e., “off-pump” [1]. In order to meet the challenges of minimally-invasive off-pump cardiac surgery, the authors have developed a tethered epicardial robotic crawler, known as HeartLander, designed to be introduced via subxiphoid incision [2]. The device is inserted into the pericardial sac through a small incision, then adheres to the surface of the heart using suction, and can crawl in inchworm fashion to reach the desired therapy site, with a variety of potential therapy options, including myocardial injection, tissue ablation, and epicardial electrode placement.

In recent years HeartLander has been tested several dozen times in vivo in a porcine model. The porcine hearts on which it has been tested have generally had relatively little epicardial fat. However, in future clinical use in humans, the situation will be quite different.

Human hearts have a variable amount of adipose tissue between the epicardium and the myocardium [3]. This layer of fat is a metabolically active organ, and is directly attached to the myocardial tissue [4]. It has been suggested that epicardial fat serves as a local energy supply for the adjacent myocardium, and as a buffer against toxic levels of free fatty acids [5]. It is commonly found in the grooves or sulci between the chambers of the heart, but can cover 67 to 100% of the myocardial surface in elderly or diseased human hearts. The layer of epicardial fat tends to be the thickest (up to 11 mm) on the anterior and lateral walls of the right ventricle, and on the anterior wall of the left ventricle. In a clinical setting, HeartLander would likely be used on diseased hearts, and thus the presence of epicardial fat must be assumed. The crawler must be able to perform locomotion when such fat is present.

Due to the likelihood that the diseased hearts on which HeartLander will be traveling will be covered in some amount of epicardial adipose tissue (fat), it is important to determine how this anatomical structure will affect locomotion. The first issue was to determine whether the suction line or suction chamber will become clogged after repeated steps across epicardial fat. The second issue was to quantify the ability of the robot to generate traction on the epicardial fat, as this is critical for successful locomotion.

## II. METHODS

Ovine hearts were used in this study, as they tend to have more epicardial fat than porcine hearts. Three fresh ovine hearts obtained from a local slaughterhouse were used. The hearts were tested within one hour of being excised from the animal, and were kept warm within a saline bath heated to the average ovine internal body temperature (39° C).

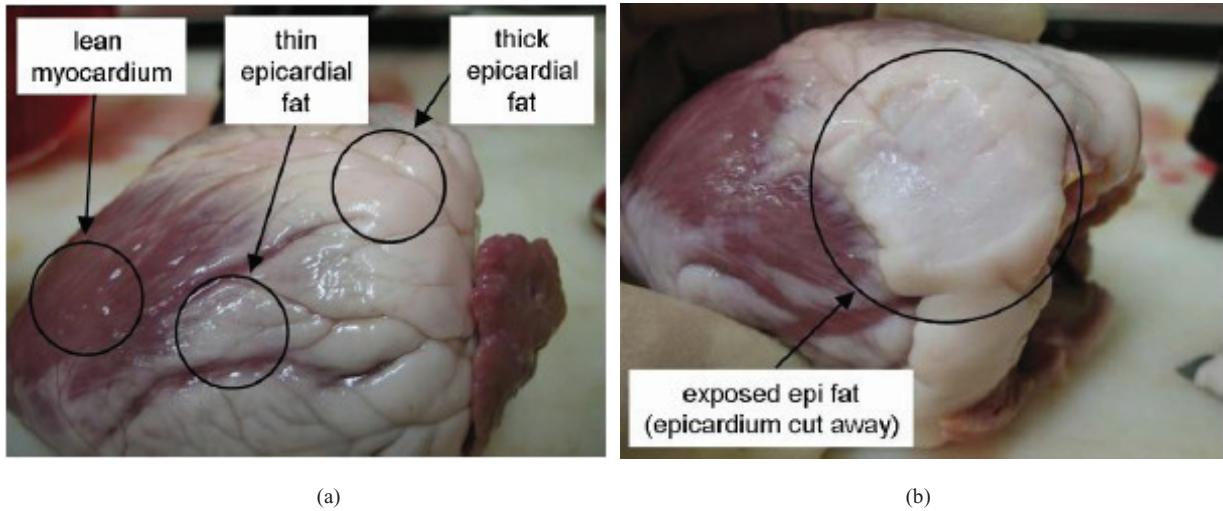


Fig. 1. (a) Photograph of a freshly excised ovine heart with three of the epicardial fat coverage classifications that we defined for this study: lean myocardium, thin epicardial fat, thick epicardial fat, and exposed epicardial fat. (b) Photograph of a freshly excised ovine heart with the fourth epicardial fat coverage classification: exposed epicardial fat. For this classification, the epicardial was dissected away from the heart in order to expose the underlying adipose tissue.

We defined four classifications of epicardial fat coverage: lean myocardium, thin epicardial fat, thick epicardial fat, and exposed epicardial fat (Fig 1(a)). The lean myocardium had no epicardial fat. Thin epicardial fat was defined as

having a thickness of less than 1 mm, under which the myocardium was visible. Thick epicardial fat was defined as having a thickness of 3 mm or more, under which the myocardium was not visible. For the exposed epicardial fat




Fig. 2. Photographs of the open suction chamber after every ten dragging trials on a region of the heart with thick epicardial fat coverage. It can be seen that the front corners of the suction chamber, which were facing opposite to the direction in which the body was dragged, accumulated epicardial fat over the experiment. The vacuum line did not become clogged with the displaced epicardial fat.




Fig. 3. Photographs of the open suction chamber after every ten dragging trials on a region of the heart with exposed epicardial fat coverage. It can be seen that the entire front edge of the suction chamber, which was facing opposite to the direction in which the body was dragged, became completely filled with epicardial fat after approximately 10 trials. The vacuum line did not become clogged with the displaced epicardial fat.

classification, the epicardial layer that naturally covers the adipose tissue was dissected away (Fig 1(b)). The front body of a typical robot crawler with an open suction chamber was used in both the suction clogging and traction generation experiments. The suction chamber was supplied with a vacuum pressure of 400 mmHg, which is within the range that has been demonstrated to be safe for the epicardium [6].

In the suction clogging experiments, the front body was dragged 20 mm across the heart surface with the vacuum pressure active at two locations that featured the thick epicardial fat and exposed epicardial fat classifications. These trials were repeated 50 times at each location. The bottom of the suction chamber was photographed after every 10 trials, and the suction chamber was thoroughly cleaned of any accumulating epicardial fat deposits between the two locations.

In the traction generation experiment, the same crawler body was dragged 20 mm across the heart surface with the vacuum pressure active at four locations featuring the four classifications of epicardial fat coverage. The maximum traction force for each trial was recorded by pulling the body with a handheld force gauge. These trials were repeated five times at each of the four locations.

### III. RESULTS

Repeatedly dragging the crawler body over epicardial fat while suction was active illustrated that the epicardial fat

will not clog the suction line, but does accumulate in the suction chamber. Figure 2 shows photographs of the suction chamber after every 10 trials on a region of the heart with thick epicardial fat coverage. It can be seen that the front corners of the suction chamber, which were facing opposite to the direction in which the body was dragged, accumulated epicardial fat over the experiment. For the same experiment conducted over the exposed epicardial fat, the accumulation of fat in the suction chamber was more pronounced. It can be seen in Fig. 3 that the entire front face of the suction chamber became completely filled with the dislodged epicardial fat after just 10 trials. After approximately 20 trials, no further accumulation of fat was possible within the suction chamber. The suction line did not become clogged with dislodged epicardial fat in either experiment.

The traction experiment showed that the suction chamber was able to generate traction on the surface of ovine hearts with thin or thick epicardial fat coverage, but not on exposed epicardial fat. The suction chamber generated an average of 1.5 N and 1.4 N of traction on the lean myocardium of the left and right ventricles, respectively (Fig. 4). These measurements served as controls because there was no epicardial fat coverage on the heart at these locations. The average traction on the heart with thin epicardial fat was 2.2 N, while the average traction was 1.4 N over thick epicardial fat coverage. On the exposed epicardial fat, however, the average traction was only 0.3 N. The traction on the exposed epicardial fat decreased over the course of the

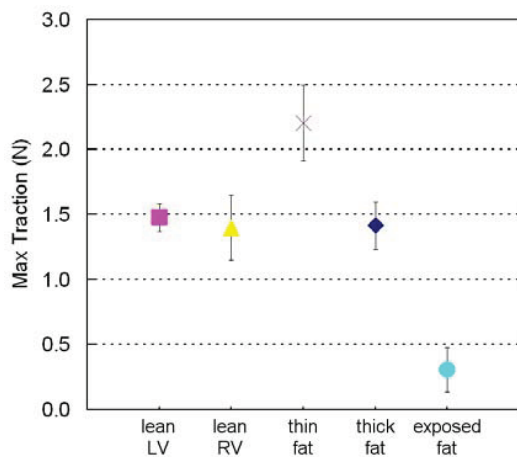


Fig. 4. The mean and standard deviation of the maximum traction testing over the four classifications of epicardial fat coverage. The suction pad generated similar traction over the lean myocardium, thin, and thick epicardial fat coverage. The maximum traction on the exposed epicardial fat decreased significantly.

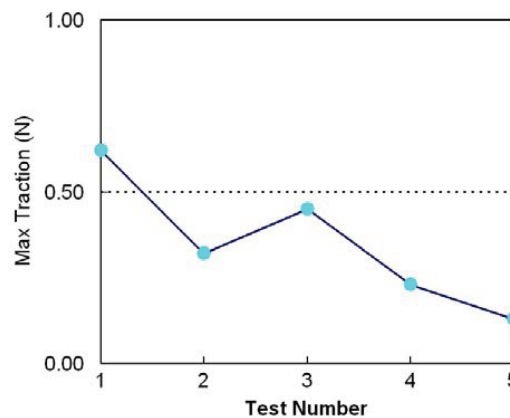


Fig. 5. A plot of the traction testing of the open suction pad over the exposed epicardial fat. The traction was poor to begin with, and decreased over the course of the test. It is likely that this trend reflects the fact that the front edge of the suction pad quickly became completely covered with dislodged adipose tissue.

five trials, as seen in Fig. 5, likely due to the accumulation of dislodged fat along the inside of the suction chamber seen in the previously described experiment.

#### IV. DISCUSSION

The presence of normal epicardial fat did not clog the suction chamber of the crawler or the suction lines, and the suction chamber was able to generate traction over epicardial fat as well. Although some epicardial fat did accumulate in the open suction chamber when dragged repeatedly over thick epicardial fat, the traction study illustrated that this accumulation did not decrease the ability of the suction chamber to generate traction. The far greater accumulation when the crawler was dragged over exposed epicardial fat did adversely affect the traction generated by the suction pad. Fortunately, it is not expected that HeartLander will often encounter adipose tissue exposed to such a degree, because the epicardium naturally covers this tissue on the heart. However, the fat that accumulates in the suction chamber over the course of the first ten repetitions suggests the benefit of maintaining the integrity of the epicardial membrane by not repeatedly drawing a foot with active suction over the same location; i.e., minimizing slippage is better for both the epicardium and the performance of the crawler.

#### REFERENCES

1. Mack MJ (2001) Minimally invasive and robotic surgery. *JAMA* 285:568–572
2. Patronik NA, Ota T, Zenati MA, Riviere CN (2009) A miniature mobile robot for navigation and positioning on the beating heart. *IEEE Trans Robotics* 25:1109-1124
3. Shirani J, Berezowski K, Roberts WC (1995) Quantitative measurement of normal and excessive (cor adiposum) subepicardial adipose tissue, its clinical significance, and its effect on electrocardiographic QRS voltage. *Am J Cardiol* 76:414–418
4. Iacobellis G, Corradi D, Sharma AM (2005) Epicardial adipose tissue: Anatomic, biomolecular and clinical relationships within the heart. *Nat Clin Pract Cardiovasc Med* 2:536-543
5. Marchington JM, Mattacks CA, Pond CM (1989) Adipose tissue in the mammalian heart and pericardium: Structure, foetal development and biochemical properties. *Comp Biochem Physiol B: Comp Biochem* 94:225-232
6. Borst C, Jansen EWL, Tulleken CAF, Gründeman PF, Mansvelt Beck HJ, van Dongen JWF, Hodde KC, Bredée JJ (1996) Coronary artery bypass grafting without cardiopulmonary bypass and without interruption of native coronary flow using a novel anastomosis site restraining device (“Octopus”). *J Am Coll Cardiol* 27:1356-1364

Author: C. N. Riviere  
 Institute: Carnegie Mellon University  
 Street: 5000 Forbes Avenue  
 City: Pittsburgh, PA  
 Country: USA  
 Email: camr@ri.cmu.edu